

Two instances of gonadal abnormalities in Indian mackerel

Dhanya, A. M., Preetha, G. Nair, Abhilash, K. S., Pravitha, V. P., Dhaneesh Vijayan, Vishnu, P. G., Shamal, P. and Kripa, V.

ICAR-Central Marine Fisheries Research Institute, Kochi

The Indian mackerel *Rastrelliger kanagurta* is known to be dioecious with male and female gonads in separate individuals. However, gonadal abnormalities such as hermaphroditism and other aberrations have been observed in a few instances. Gonadal abnormalities in mackerel observed during regular biological sampling from fish samples collected from the landing centre is reported here. For the histological analysis, the gonads were fixed in 10% neutral buffered formalin, dehydrated in ethanol series and the cleared samples were embedded in paraffin wax and made into blocks.

Serial sections of 5 μ m were taken using a Leica Microtome and stained with Harris's Haematoxylin and Eosin.

A mackerel caught in a gillnet on 6th February 2014, had both male and female gonads which were separate. The total length and body weight of the hermaphrodite fish was 178 mm and 52 g respectively. The gonads consisted of separate testis and ovary and they were not interconnected (Fig. 1). The length of the right ovary was 33 mm while the left ovary was smaller at 22 mm. The total

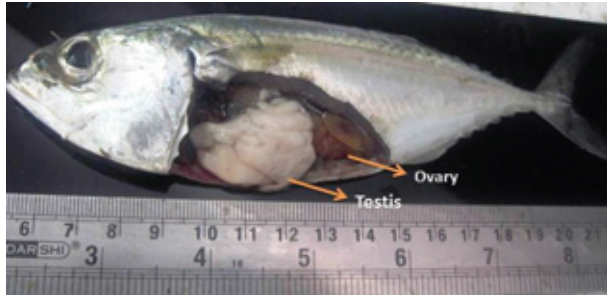

Fig. 1. Hermaphrodite mackerel with male and female gonads

weight of testis and ovary were 0.67 and 2.82 g respectively. Histological analysis showed that the ovary and testis were similar to other normal gonads and they were in spent stage. The present observation was different from that of earlier records of hermaphroditism in mackerel, where in the same gonad, one part was functional as ovary and the other as testis. Parasitism may be a cause for hermaphroditism, but in the present instance parasite infestation was not observed.

Another mackerel was obtained on 6th June 2014 from a ring seine catch measuring 190 mm and weighing 83 g. It had gonads where the ovary was dominant and was encircled by a thin testis like tissue. The length of the ovary was 32 mm and

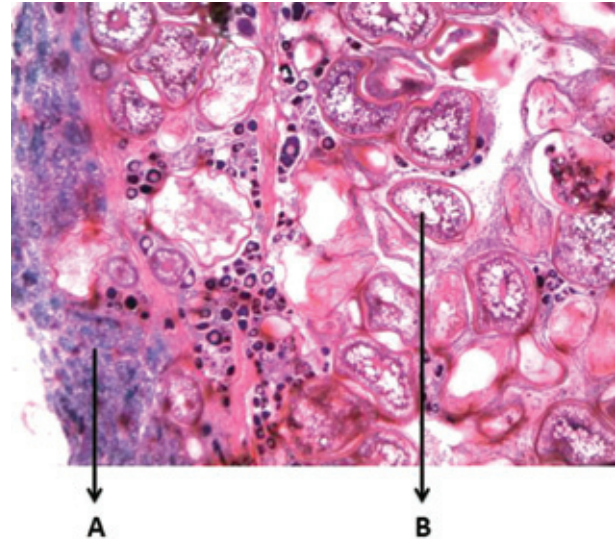


Fig. 2. Cross section of ovary showing abnormal section (A) and normal tissue with developing oocytes (B)

weighed 2 g. Histological studies showed that the female gonad was prominent and that the testis like tissue was only abnormal, hardened ovarian tissue (Fig.2).

During the period 2010 to 2014, about 36000 specimens of mackerel collected from the same landing centre have been analysed but hermaphroditism was observed only once indicating that this is an abnormality.